

# Hepatitis C infection: challenges in dental management and diagnosis of extrahepatic manifestations

Cláudia Misue Kanno, DDS,  
PhD<sup>1</sup>

Alvimar Lima de Castro,  
DDS, PhD<sup>2</sup>

Marcelo Macedo Crivelini,  
DDS, PhD<sup>2</sup>

## ABSTRACT:

Hepatitis C is associated with autoimmune diseases, hepatocellular carcinoma, and extrahepatic manifestations that, in conjunction, may seriously compromise the patient's quality of life. We herein describe a case of chronic hepatitis C with oral manifestations and discuss some implications for diagnosis and treatment. A 63-year-old woman complaining of spontaneous bleeding of the oral mucosa presented with bilateral asymmetric ulcers surrounded by white papules and striae on the buccal mucosa. Her medical history revealed leucopenia, thrombocytopenia, and skin lesions associated with chronic hepatitis C. Propranolol and ranitidine had recently been prescribed. Lichen planus, lichenoid reaction, and erythema multiforme were considered in the differential diagnosis. Histopathological analysis revealed lymphocytic infiltrate in a lichenoid pattern. The lesions partially healed after 1 week and completely regressed after 6 months, despite the maintenance of all medications; no recurrence was observed. The final diagnosis was oral lichen planus associated with hepatitis C. Chronic hepatitis C may present oral manifestations, which demand adjustments in dental treatment planning. Medication side effects may interfere with the clinical presentation and course of the disease and should be accounted for in the differential diagnosis. The possibility of spontaneous remission of oral lichen planus should always be considered, especially when putative etiological factors of a lichenoid lesion are withdrawn in an attempt to differentiate oral lichen planus from lichenoid lesions. This case emphasizes the importance of recognizing the extrahepatic manifestations of hepatitis C as a cause of increased morbidity.

**Keywords:** chronic hepatitis c, leucopenia, oral diagnosis, oral lichen planus, thrombocytopenia.

<sup>1</sup> Post-doctorate Program, Araçatuba School of Dentistry, Paulista State University, Araçatuba, São Paulo, Brazil.

<sup>2</sup> Department of Pathology and Clinical Pro-paedeutics, Araçatuba School of Dentistry, Paulista State University, Araçatuba, São Paulo, Brazil.

**Declaration of Interests:** The authors certify that they have no commercial or associative interest that represents a conflict of interest in connection with the manuscript.

### Corresponding Author:

Cláudia Misue Kanno.  
E-mail: cmkanno@foa.unesp.br

DOI: 10.18762/2525-5711.20160014

Submitted:

Accepted for Publication:

Originally published as 1 (1) January/March 2012.

## INTRODUCTION

There is growing concern in medical and dental practice about the morbidity associated with hepatitis C. Hepatitis C virus (HCV), which causes the infection, is an RNA virus whose incubation period is about 6–7 weeks. The virus is contracted chiefly via the parenteral route, through blood product infusion or intravenous drug use. However, 30–40% of the infected patients have no history of such procedures<sup>1</sup>. In these cases, the possibility of transmission during dental procedures, ear piercing, tattooing, acupuncture, and endoscopic biopsies should be considered<sup>1</sup>.

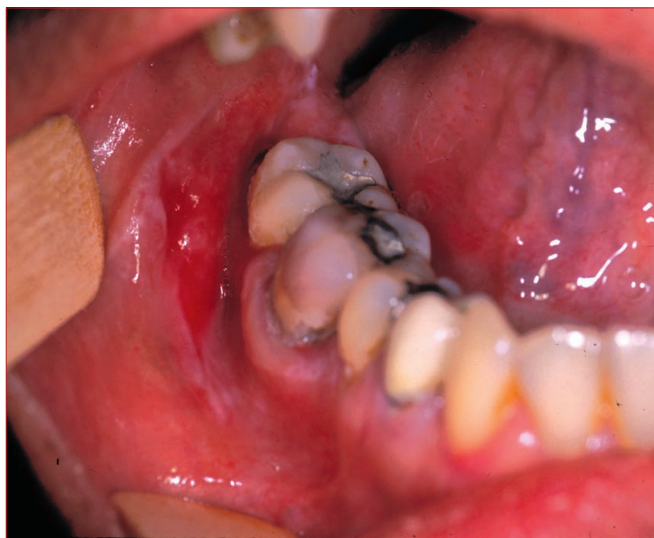Symptoms of acute and chronic infections are usually mild and nonspecific, which makes dating of the infection onset difficult. Chronic infection develops in about 75% of the cases<sup>1–3</sup>. About 20–50% of the patients with chronic infection develop cirrhosis, which may culminate in hepatic failure or hepatocellular carcinoma<sup>3</sup>. Chronic hepatitis C is also associated with several immunological disturbances including mixed cryoglobulinemia, membranoproliferative glomerulonephritis, non-Hodgkin lymphoma, Sjögren syndrome, porphyria cutaneous tarda, endocrine and neurological manifestations, leukocytoclastic vasculitis, and lichen planus<sup>1–3</sup>. These extrahepatic manifestations are associated with increased mortality<sup>4</sup>.

Oral lichen planus (OLP) is a chronic mucocutaneous disease with uncertain etiology; it is classified as reticular, plaque, atrophic, erosive, or bullous according to the clinical presentation<sup>5</sup>. Emotional stress, immunological disturbances, neurological dysfunctions, and viruses are possible etiological factors<sup>1,5</sup>. Recent studies have shown a correlation between OLP and HCV.

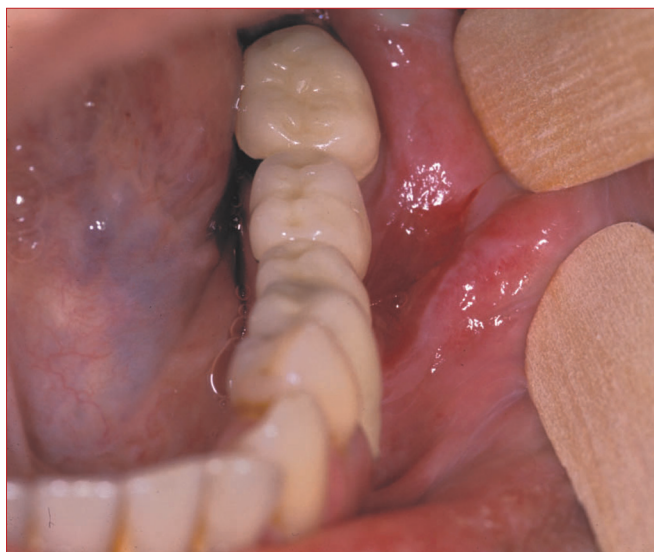The accumulated knowledge about hepatitis C seems to be insufficient because the infection is quite recently characterized. Therefore, many aspects concerning the mechanisms of immunological disturbances and their consequences are still uncertain. Here, we describe a case of chronic hepatitis C with oral manifestations and discuss some implications for diagnosis and treatment.

## CASE REPORT

A 63-year-old woman complained of oral soreness associated with spontaneous bleeding during masticatory movements and tooth brushing. The symptoms had started 3 days previously. Bilateral irregular ulcers surrounded by white papules and striae with bleeding on minor trauma were observed on the buccal mucosa. On the right side, they extended asymmetrically to the pterygomandibular fold (Figure 1), and the lesions were smaller on the left side (Figure 2). The patient had occlusal amalgam restorations and posterior porcelain veneers in the mandibular teeth and a maxillary removable partial denture.



**Figure 1.** Right buccal mucosa showing an ulcer surrounded by white striae.



**Figure 2.** Left buccal mucosa showing an ulcer with spontaneous bleeding.

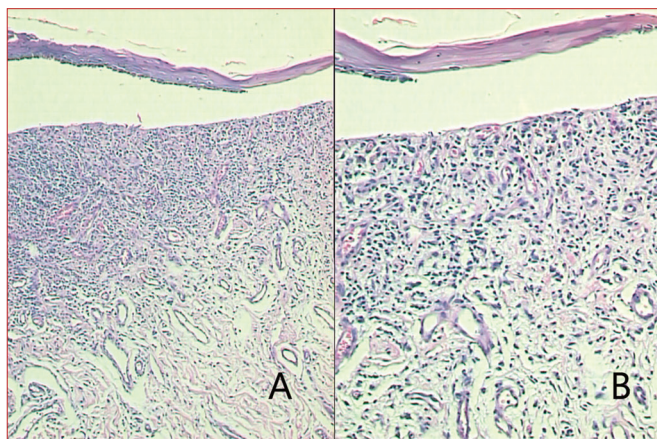
Chronic hepatitis C had been diagnosed 12 years earlier. The mode of transmission was unknown. Treatment with interferon and, later, ribavirin had been tried. Unfortunately, the side effects were so strong that the therapy had to be discontinued.

Dermatological vasculitis and hematological disturbances had been previously diagnosed as the extrahepatic manifestations of hepatitis C. Idiopathic chronic thrombocytopenia and leucopenia had developed some years after the diagnosis of hepatitis C. Bone marrow biopsy revealed normal values, indicating no medullary impairment affecting blood cell production.

Her medical history also included arterial hypertension, gastric discomfort, rheumatism, and allergy to cephalosporin, clindamycin, and rifocin. Propranolol therapy for hypertension

had been initiated 1 month before the onset of the buccal lesions. Ranitidine had been simultaneously prescribed for gastric discomfort control.

A biopsy was performed with the presumptive diagnosis of OLP, drug-induced lichenoid lesion, or erythema multiforme. On this occasion, her platelet count was  $52,000/\text{mm}^3$ . Histopathological examination revealed chronically inflamed mucosa with some ulcerated areas or outlined by atrophic epithelia. A band-like distribution of lymphocytic inflammatory infiltrate was seen in the subjacent lamina propria, at times associated with basal keratinocyte destruction (Figure 3). The histological features were compatible with OLP or lichenoid lesions.



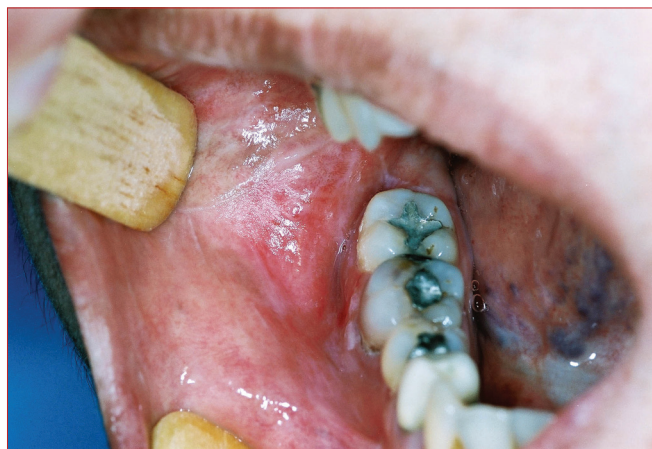**Figure 3.** Epithelial displacement from chronically inflamed connective tissue showing subepithelial band-like lymphocytic infiltration (hematoxylin and eosin stain; magnification,  $\times 100$  [A] and  $\times 200$  [B]).

The postoperative period was uneventful. Partial healing of the oral ulcers was observed after 1 week. After 6 months, the ulcers healed completely, without recurrence (Figure 4). The platelet count was  $110,000/\text{mm}^3$  and other hematological parameters were within the normal limits. During the entire follow-up period, the systemic therapy was not modified, which led to the final diagnosis of OLP associated with hepatitis C.

## DISCUSSION

Some dental procedures can be life threatening for patients with HCV infection if the complications of chronic infection are not anticipated during treatment planning. In our case, the superimposition of several extrahepatic manifestations of chronic hepatitis C and the possibility of side effects of the instituted therapies made the final diagnosis of the oral lesions challenging. Of special concern for dental management, the patient presented leucopenia, thrombocytopenia, and oral lesions.

Thrombocytopenia may occur due to increased destruction, diminished production, or abnormal distribution of platelets in blood<sup>5</sup>. In the present case, HCV infection may have



**Figure 4.** Right intraoral view after 6 months showing healed areas without recurrence of ulcers.

triggered autoimmune destruction of platelets, as medullary impairment was absent. Treatment for thrombocytopenia is determined by the severity of symptoms. Corticosteroids or intravenous immunoglobins are administered as immunosuppressants in most cases<sup>6,7</sup>, but no therapy is required in mild conditions. In the present case, corticosteroid therapy was contraindicated because of chronic leucopenia. Splenectomy is indicated in refractive and chronic conditions of spleen functional impairment<sup>8</sup>. Spleen removal is justified for its role in antibody production and platelet sequestration from blood<sup>9,10</sup>. However, the patient's hemostatic parameters were not stable for splenectomy to be performed. Therefore, thrombocytopenia was monitored through periodical hematological analysis.

The combination of interferon with ribavirin is considered the most effective treatment for hepatitis C and has improved survival rates. Unfortunately, the therapy effectiveness is still limited and is associated with important side effects. The adverse effects of interferon include neuropsychiatric problems, fever, chills, headache, fatigue, arthralgia, granulocytopenia, and thrombocytopenia<sup>3</sup>. Ribavirin is a teratogen and causes a decrease in hemoglobin. Therapy withdrawal due to complications is quite common. In the present case, interferon and ribavirin worsened the hematological parameters and had to be withdrawn.

The epidemiological relationship between OLP and hepatitis C has been reported<sup>11,12</sup>, notably in the erosive type<sup>13,14</sup> and asymmetric lesions on the buccal mucosa<sup>15</sup>. However, the prevalence of OLP associated with hepatitis C presents geographical variations. This association is well documented in Italy<sup>13,15</sup>, Japan<sup>16,17</sup>, and Thailand<sup>12</sup>. In Brazil, a high prevalence of OLP in patients with HCV infection was found in São Paulo<sup>11</sup> but not in Rio de Janeiro<sup>18</sup>. There is no consensus to explain this intriguing fact. Genetic variation among the populations seems to be the main factor accounting for these differences<sup>19</sup>. On the other



hand, the incidence of OLP as an extrahepatic manifestation is probably low in the early phase of the infection, and therefore, dating of HCV contraction should be considered in the diagnosis.

RNA filaments of HCV have been detected in OLP, suggesting that the lesion represents an extrahepatic site of viral proliferation<sup>16,17,20,21</sup>. The well-known association of HCV with hepatocellular carcinoma raises the question whether the virus plays a role in malignant transformation of OLP. Although evidence of increased rates of malignant transformation of OLP associated with HCV infection is lacking, its possibility justifies a long-term follow-up of the cases.

The presumptive role of HCV in the pathogenesis of OLP is still unknown. It does not seem to cause OLP by itself, because the virus is also found in normal cutaneous tissue of HCV carriers<sup>17</sup>. The lympho-mononuclear infiltrate, which is one of the main histological features of OLP, strongly suggests that the progressive epithelial destruction is due to a local immune response<sup>11,19</sup>. Patients with hepatitis C and OLP present relatively high quantities of antibodies against oral mucosa antigens, which are not observed in uninfected patients with the lesion<sup>22</sup>. Therefore, a host immune response, rather than viral factors, seems to be a determinant for the occurrence of OLP<sup>11,23</sup> as well as cytopenias associated with hepatitis C<sup>4</sup>. Interestingly, in the present case, besides the remission of the oral lesions, the platelet count reached 110.000/mm<sup>3</sup> 5 months after the initial appointment, without specific treatment. These facts suggest that immunological mechanisms can show variations not related to treatment, which could account for the patient's general health improvement. Nevertheless, clinical relapse elicited by any stress (infectious, viral, deficiencies, or medicines) is expected.

OLP should always be differentiated from oral lichenoid lesions, which share clinical and histological features. Lichenoid lesions differ from OLP by having a known cause that may be either local, such as amalgam restorations, or systemic, usually drugs prescribed for several purposes. The diagnostic assessment consists of a comprehensive and detailed drug history investigation, emphasizing the type of medication and starting and finishing date of administration in correlation with the onset of the lesions<sup>24</sup>. The final diagnosis is established after the total withdrawal of all putative etiological factors of lichenoid lesions, because regression of the lesions is expected. Unfortunately, the withdrawal of all medications is not always possible due to the systemic condition of the patient or complex relationship of diseases.

In our case, partial healing of the oral lesions was observed 1 week after the initial appointment, although the therapy was not modified. The fact excluded the hypothesis of oral lichenoid lesions induced by medications. If the putative etiological factors for lichenoid lesions had been withdrawn, the

final diagnosis could be erroneously defined as lichenoid lesions. Apparently, lesion regression was associated with spontaneous alterations in the immune response and occurred independently of drug withdrawal. Therefore, the possibility of spontaneous remission of hepatitis C-associated OLP should be considered when medicines are withdrawn to differentiate OLP from lichenoid lesions.

## CONCLUSION

In conclusion, hepatitis C may lead to several immunological disturbances that compromise life quality. In this respect, both the extrahepatic manifestations of the infection and the medication side effects should be considered in the diagnosis of oral lesions and dental treatment planning. The possibility of spontaneous remission of OLP should always be considered, especially when the putative etiological factors of lichenoid lesions are withdrawn to differentiate OLP from lichenoid lesions.

## REFERENCES

1. Pawlotsky JM, Dhumeaux D, Bagot M. Hepatitis C virus in dermatology: a review. *Arch Dermatol*. 1995;131(10):1185-93.
2. Gumber SC, Chopra S. Hepatitis C: a multifaceted disease. Review of extrahepatic manifestations. *Ann Intern Med*. 1995;123(8):615-20.
3. Bonkovsky HL, Mehta S. Hepatitis C: a review and update. *J Am Acad Dermatol*. 2001;44:159-79.
4. Vassilopoulos D, Calabrese LH. Extrahepatic immunological complications of hepatitis C virus infection. *AIDS*. 2005;19 Suppl 3:S123-7.
5. Sonis ST, Fazio RC, Fang L. Principles and practice of oral medicine. 2nd ed. Philadelphia: WB Saunders; 1995. p. 242-61.
6. Bouroncle BA, Doan CA. Treatment of refractory idiopathic thrombocytopenic purpura. *JAMA*. 1969;207:2049.
7. Laros RK, Penner JA. Refractory thrombocytopenic purpura treated successfully with cyclophosphamide. *JAMA*. 1971;215(3):445.
8. Yeager DA. Idiopathic thrombocytopenic purpura: report of case. *JADA*. 1975;90(3):640-3.
9. Syracuse EP. Purpura – a review. *J Oral Med*. 1975;30(1):21-3.
10. Fotos PG, Graham WL, Bowers DC, Perfetto SP. Chronic autoimmune thrombocytopenic purpura. A 3-year case study. *Oral Surg Oral Med Oral Pathol*. 1983;55(6):564-7.
11. Figueiredo LC, Carrilho FJ, de Andrade HF, Migliari DA. Oral lichen planus and hepatitis C virus infection. *Oral Dis*. 2002;8(1):42-6.
12. Klanrit P, Thongprasom K, Rojanawatsirivej S, Theamboonlers A, Poovorawan Y. Hepatitis C virus infection in Thai patients with oral lichen planus. *Oral Dis*. 2003;9(6):292-7.
13. Gandolfo S, Carbone M, Carrozzo M, Gallo V. Oral lichen planus and hepatitis C virus (HCV) infection: is there a relationship? A report of 10 cases. *J Oral Pathol Med*. 1994;23(3):119-22.
14. Carrozzo M, Gandolfo S, Carbone M, Colombatto P, Broccoletti R, Garzino-Demo P, et al. Hepatitis C virus infection in Italian patients with oral lichen planus: a prospective case-control study. *J Oral Pathol Med*. 1996;25(10):527-33.

15. Gimenez-Garcia R, Peres-Castrillón JL. Lichen planus and hepatitis C virus infection. *J Europ Acad Dermatol Venereol*. 2003;17(3):291-5.
16. Nagao Y, Sata M. Hepatitis C virus and lichen planus. *J Gastroenterol Hepatol*. 2004;19:1101-13.
17. \_\_\_\_\_, \_\_\_\_\_, Noguchi S, Seno'o T, Kinoshita M, Kameyama T, et al. Detection of hepatitis C virus in oral lichen planus and oral cancer tissues. *J Oral Pathol Med*. 2000;29(6):259-66.
18. Cunha KS, Manso AC, Cardoso AS, Paixao JB, Coelho HS, Torres SR. Prevalence of oral lichen planus in Brazilian patients with HCV infection. *Oral Surg Oral Med Oral Pathol Oral Radiol Endod*. 2005;100(3):330-3.
19. Lodi G, Scully C, Carrozzo M, Griffiths M, Sugerman PB, Thongprasom K. Current controversies in oral lichen planus: report of an international consensus meeting. Part 1. Viral infections and etio-pathogenesis. *Oral Surg Oral Med Oral Pathol Oral Radiol Endod*. 2005;100(1):40-51.
20. Lazaro P, Olalquiaga J, Bartolomé J, Ortiz-Movilla N, Rodríguez-Iñigo E, Pardo M, et al. Detection of hepatitis C virus RNA and core protein in keratinocytes from patients with cutaneous lichen planus and chronic hepatitis C. *J Invest Dermatol*. 2002;119(4):798-803.
21. Kurokawa M, Hidaka T, Sasaki H, Nishikata I, Morishita K, Setoyama M. Analysis of hepatitis C virus (HCV) RNA in the lesions of lichen planus in patients with chronic hepatitis C, detection of anti-genomic- as well as genomic-strand HCV RNAs in lichen planus lesions. *J Dermatol Sci*. 2003;32(1):65-70.
22. Lodi G, Olsen I, Piattelli A, D'Amico E, Artese L, Portes SR. Antibodies to epithelial components in oral lichen planus (OLP) associated with hepatitis C virus (HCV) infection. *J Oral Pathol Med*. 1997;26(1):36-9.
23. Harden D, Skelton H, Smith KJ. Lichen planus associated with hepatitis C virus: no viral transcripts are found in the lichen planus, and effective therapy for hepatitis C virus does not clear lichen planus. *J Am Acad Dermatol*. 2003;49(5):847-52.
24. McCartan BE, McCreary CE, Heary CM. Studies of drug-induced lichenoid lesion: Criteria for case selection. *Oral Dis*. 2003;9(4):163-4.